

Orthokeratology and Presbyopia

Motivated patients can achieve suitable far and near UCVA.

BY ANTONIO CALOSSI, DIP OPTOM, FBCLA, FIACLE

Orthokeratology is a clinical technique that uses fitted rigid contact lenses to reshape the corneal profile, temporarily modifying or eliminating refractive error. It is not a new procedure,¹ but it has undergone a resurgence of interest in the past decade.^{2,3} In orthokeratology, patients wear reverse-geometry contact lenses overnight for temporary correction of low to moderate ametropia.^{4,5}

Orthokeratology contact lenses produce corneal reshaping because of the plasticity of the cornea, particularly that of the epithelial layer. If the amount of corneal molding is properly controlled, the eye can be brought into correct focus to compensate for the patient's refractive error. Overnight wear of modern orthokeratology contact lenses produces rapid change, with most results noticeable after the first night. Refractive stability occurs in 1 to 2 weeks.⁶ The patient's refractive state regresses to pretreatment levels once the lens is no longer worn.

Orthokeratology has been shown to be an effective treatment for low to moderate myopia⁷ and for astigmatism in selected cases.⁸ In our experience, orthokeratology with an apical-clearance lens design is also promising as a treatment for hyperopia and presbyopia through corneal steepening.^{8,9}

The ESA for hyperopia (Figure 1) is a customizable hexa-curve reverse geometry lens of my own design that my patients have used with successful outcomes. In selected and motivated patients, we were able to achieve suitable far and near UCVA.^{8,9} Our results demonstrate that the central corneal region steepened after lens wear and the paracentral regions flattened and then steepened again (Figure 2). I will describe two successful cases.

CASE REPORT NO. 1

A 43-year-old occasional soft contact lens wearer with hyperopia and normal ocular and general health reported increased difficulty focusing on close work with her current monofocal spectacles and contact lenses. With the following manifest refractions in her right and left eyes, respectively, her distance vision was 20/20: +2.75 D sphere and +2.00 D sphere; her near add was 2.00 D. Corneal topography and biomicroscopy showed clear corneas and good overall ocular condition. The patient required good distance vision for driving and wanted to read without glasses.

We decided to fit ESA for hyperopia on overnight wear in both eyes. After 2 weeks, she reported good UCVA and overnight lens comfort. She improved to plano in both eyes,

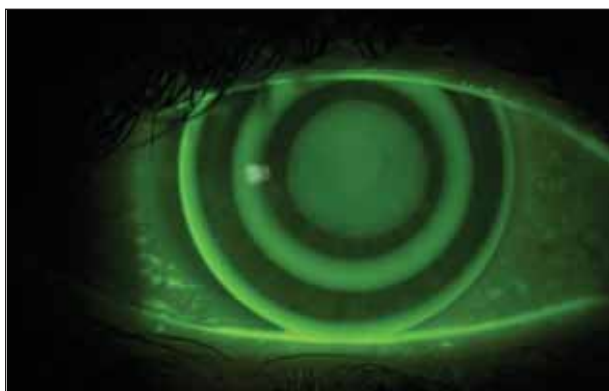

Figure 1. ESA for hyperopia is a customizable hexa-curve reverse geometry lens.

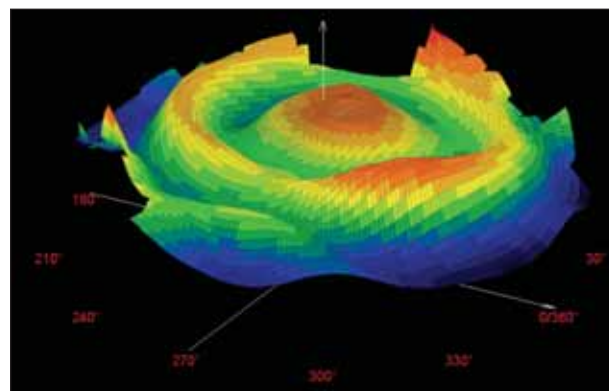


Figure 2. 3-D curvature corneal profile after hyperopic orthokeratology steepening.

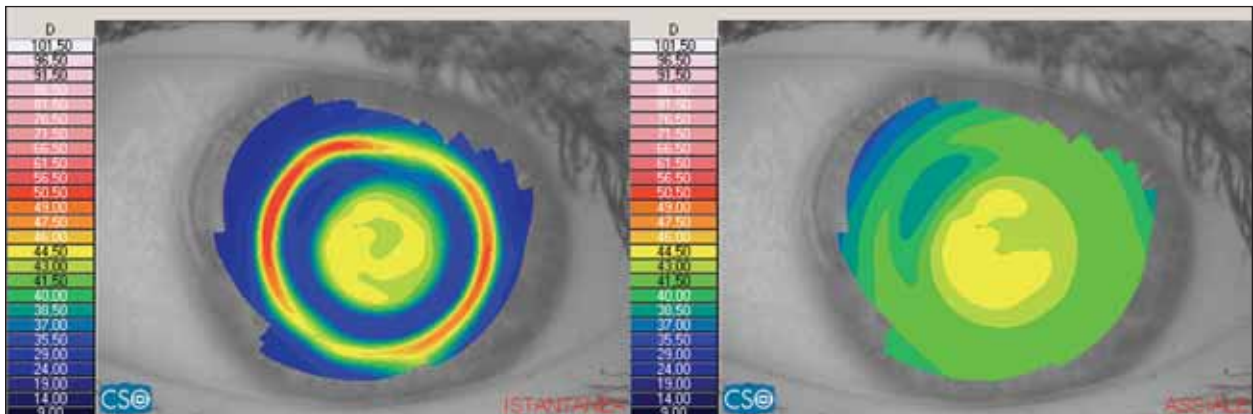


Figure 3. Case No. 1: Instantaneous and axial corneal maps after hyperopic orthokeratology.

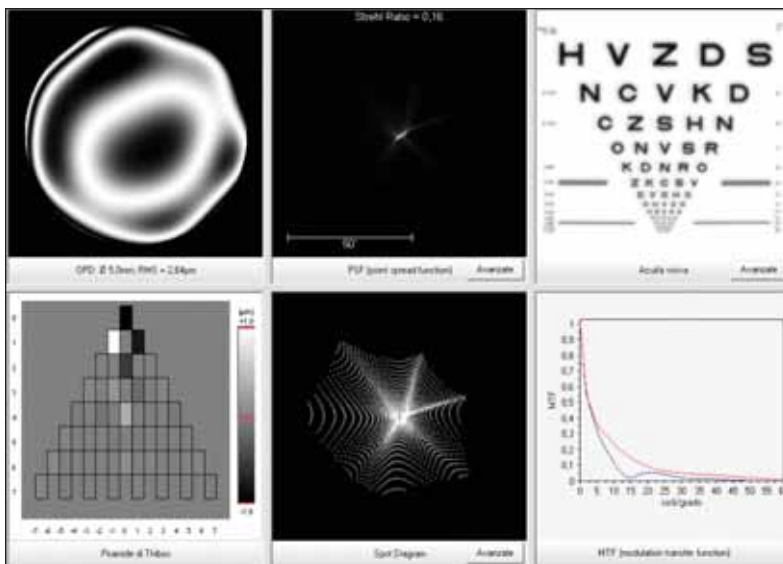


Figure 4. Case No. 1: Summary of the corneal wavefront.

with 20/20 visual acuity at a near add of 0.75 D. She was J1 at 35 cm. Central corneal steepening, paracentral flattening, and a steeper ring in the peripheral zone were noted on corneal topography (Figure 3).

Increased asphericity in the optical zone, with resultant corneal Q value equal to -0.85 , caused negative spherical aberration (Figure 4) that reduced the near addition. The patient found this modality comfortable and satisfactory for both distance and near vision. After 2 years of overnight treatments, biomicroscopy shows clear corneas and good overall ocular health. The patient continues to be spectacle independent for distance vision and uses 0.75 D reading glasses only seldom, particularly for long-term computer use.

CASE REPORT NO. 2

A 48-year-old woman with normal ocular and general health reported increased difficulty with close work. She

had never worn correction for far vision, and she was not willing to wear near-vision glasses. At baseline, manifest refraction was $+0.25 +0.50 \times 100^\circ$ in the right eye and $+0.50 +0.25 \times 90^\circ$ in the left, and her near add was 1.75 D. Her distance UCVA in both eyes was 20/20; however, she was J10 (20/100) at 40 cm. We fitted a 1.50 D ESA for hyperopia on her nondominant left eye only, and after 1 week of overnight wear, she achieved $+0.25 +0.50 \times 100^\circ$ in the right eye and $-0.50 -0.75 \times 5^\circ$ in the left. She had 20/20 and 20/40 UCVA in her right and left eyes, respectively, and near vision was J1 (20/20) at 40 cm. After treatment, the optical zone of the cornea showed increased asphericity (Figure 5), with a Q value of -0.7 . For a 5-mm pupil, this asphericity causes a 2.20 D longitudinal spherical aberration (Figure 6).

Binocular interaction allowed this patient to have good vision for both far and near. Despite a slight drop in far vision, the patient was satisfied with her overall visual performance, with the range of near vision within her normal activity requirement. Now, after 1 year of overnight orthokeratology, she is spectacle independent, the cornea is clear, and overall ocular health is good.

DISCUSSION

After hyperopic molding, the optical zone of the cornea is hyperprolate. This change in corneal asphericity induces a negative spherical aberration, which induces corneal multifocality.¹⁰ If the spherical aberration is properly controlled, it is possible to correct presbyopia.

The spherical aberration of the anterior corneal surface, the posterior corneal surface, and the crystalline lens tend to counterbalance one another if they are of opposite sign.

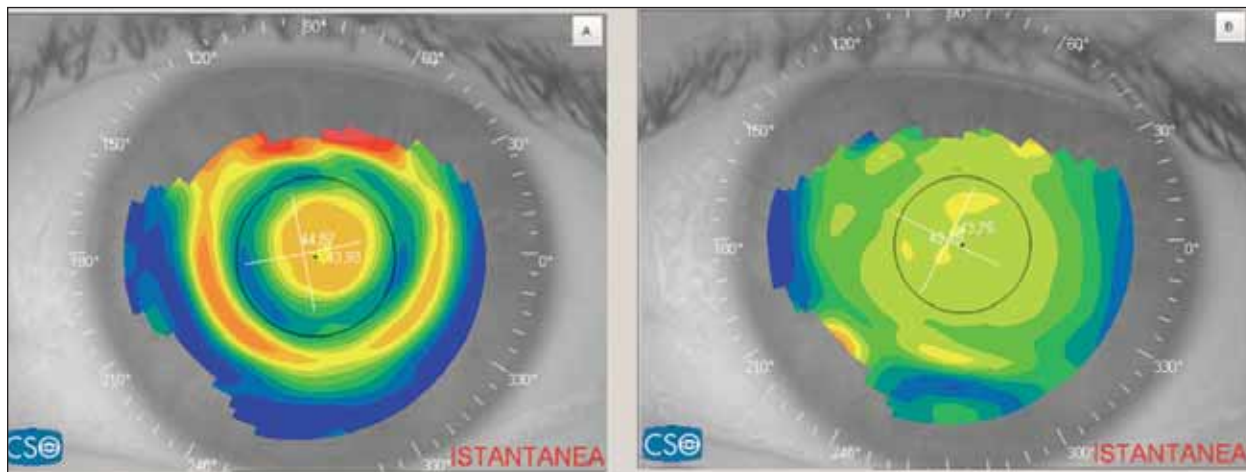


Figure 5. Case No. 2: (A) Postoperative orthokeratology corneal topography shows a noticeable change from (B) preoperative.

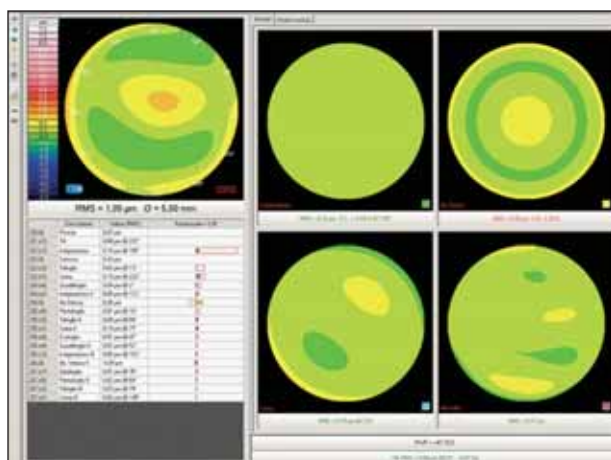


Figure 6. Case No. 2: Corneal wavefront analysis.

However, when they do not mutually compensate, the image of a point object will consist of a small disc surrounded by a diffuse halo. If the overall spherical aberration is not excessive, there is a slight loss in contrast transfer but an improvement in depth of field; the latter is due to the multifocal effect of the spherical aberration. This is why, in the event of residual ametropia, an eye that undergoes corneal refractive surgery will have a better UCVA than would be expected. A slight residue of spherical aberration may also be useful in the event of presbyopia—and this principle underlies the design of several types of multifocal contact lenses and IOLs that induce a degree of spherical aberration. If the spherical aberration is positive, as in an oblate cornea, the center of the pupil is used for distance vision and the peripheral zones for near. If the spherical aberration is negative, as in a hyperprolate cornea, the center is for near vision and the periphery for distance.

Too much spherical aberration can cause a significant loss in contrast transfer and increased image blur. Unfortunately,

it is not easy to define a threshold for spherical aberration that can be tolerated or useful, as subjective responses vary.

To demonstrate the effect of spherical aberration induced by corneal asphericity as in case No. 1, we can simulate the effect of two levels of spherical aberration in two model eyes (Figures 7 and 8) by means of diffraction image analysis. The first eye is aplanatic, with no spherical aberration and emmetropia in far vision. In this case, a small defocus corresponding to an object moved closer to the eye causes a rapid blur of the image and loss of spatial resolving power. The second eye represents a small amount of negative spherical aberration. At far, the image is less sharp, but the increasing defocus causes less effect than in the previous example. The image is still legible, despite a 2.00 D proximal defocus.

CONCLUSION

Orthokeratology is mainly indicated for myopic patients; however, we have recently discovered that treatment of hyperopia and presbyopia is possible with corneal steepening induced by apical clearance reverse-geometry lens designs. Motivated patients, especially younger presbyopes, are able to achieve suitable far and near UCVA, tolerating some decrement in visual performance as a trade-off for freedom from spectacles.

It is not easy to define a tolerable threshold for spherical aberration and defocus. To try to achieve presbyopia correc-

TAKE-HOME MESSAGE

- If corneal molding is controllable, the eye can be brought into correct focus to compensate for refractive errors.
- Orthokeratology is a promising treatment for presbyopia.
- In the current method, changes in corneal asphericity induce a negative spherical aberration, which induces corneal multifocality. If the spherical aberration is controlled, it is possible to correct presbyopia.




Aplanatic on paraxial focus



0.3µm spherical aberration on paraxial focus



Aplanatic, 2.00 D proximal defocus



0.3µm spherical aberration, 2.00 D proximal defocus

Figure 7. In an aplanatic eye with no spherical aberration, there is rapid blur and loss of spatial resolving power (above: far vision, below: near vision).

Figure 8. With a small amount of negative spherical aberration, there is less sharpness to the distance image but not as much defocus effect.

tion with orthokeratology, we follow a step-by-step approach. The first step is to induce corneal multifocality to increase depth of field. If this approach is not sufficient, the second step is to try aspheric monovision. If both methods fail, we optimize orthokeratology correction for far vision and prescribe glasses for near. Otherwise, we suspend the treatment and look for other kinds of correction. With orthokeratology, all these options can be tried because the treatment is fully reversible.¹¹ This modality can also be used preparatory to corneal refractive surgery, testing the sensorial adaptation capability of the patient. Keep in mind that changes after orthokeratology are reversible, but changes after corneal ablation are not. ■

Antonio Calossi, Dip Optom, FBCLA, FIACLE, practices in Certaldo (Florence), Italy, and is a Professor of Contact Lenses, Department of Optics



and Optometry, University of Turin, Italy. Professor Calossi holds a patent on an orthokeratology lens. He may be reached at e-mail: calossi@tin.it or calossi@ortho-k.it.

1. Jessen GN. Orthofocus techniques. *Contacto*. 1962;6:200-204.
2. Dave T, Ruston D. Current trends in modern orthokeratology. *Ophthalmic Physiol Opt*. 1998;18:224-233.
3. Nichols JJ, Marsich MM, Nguyen M, Barr JT, Bullimore MA. Overnight orthokeratology. *Optom Vis Sci*. 2000;77:252-259.
4. Jacobson J. Orthokeratology: the global perspective. Paper presented at: Global Orthokeratology Symposium. Chicago; 2005.
5. Swarbrick HA. Orthokeratology review and update. *Clin Exp Optom*. 2006;89:124-143.
6. Calossi A. Refractive outcome and corneal response to a customized ESA-curve reverse-geometry lens designs for overnight orthokeratology. Abstracts of the 28th BCLA Annual Clinical Conference, Birmingham, 2004. *Cont Lens Anterior Eye*. 2004;27:87-107.
7. Barr JT. Orthokeratology / Corneal Refractive Therapy GP lens designs: Then and now. Paper presented at: first global orthokeratology symposium. Toronto, Canada; 2002.
8. Calossi A. Orthokeratology and special contact lenses. In: Alió JL (ed), Alicante Refractive International. Alicante (Spain); 2008.
9. Calossi A. Orthokeratology and presbyopia. Paper presented at: third meeting of the International Society of Presbyopia; Barcelona, Spain; 2009.
10. Calossi A. Corneal asphericity and spherical aberration. *J Refract Surg*. 2007;23:505-514.
11. Hiraoka T, Okamoto C, Ishii Y, Okamoto F, Oshika T. Recovery of corneal irregular astigmatism, ocular higher-order aberrations, and contrast sensitivity after discontinuation of overnight orthokeratology. *Br J Ophthalmol*. 2009;93:203-208.